



Original article

## The Effect of Oxidized Fish Oil on Blood Parameters and Liver Histology of Nile Tilapia (*Oreochromis niloticus*)

Sana Yagoub Abdallah Tahir <sup>a,\*</sup> & Aysun Kop <sup>b</sup>

<sup>a</sup>Ege University, Graduate School of Natural and Applied Science, Department of Aquaculture Bornova, İzmir, Turkey

<sup>b</sup>Ege University, Faculty of Fisheries, Department of Aquaculture, Bornova, İzmir, Turkey

### Abstract

Fish oil is a virtually unique source of natural LC omega-3 fatty acids EPA, DPA, and DHA, as an important source of lipid in aquafeeds. However during processing and storage, fish oil is prone to oxidation. The oxidized oil has many negative effects on the growth and health of farmed fish, therefore this study was conducted to investigate the effect of oxidized anchovy oil on blood parameters and liver histology of Nile tilapia (*Oreochromis niloticus*). Nile tilapia fingerlings with an initial average body weight of (15.07±0.58 g) were stocked in nine fiberglass tanks (with a tank capacity of 120 liters) in three groups in triplicates at a density of 50 fish/tank. Fish were fed with three test diets containing 35% crude protein and 8% crude fat (POV: 4.85, 50.10, and 100.80 meq/kg-1) twice a day at a feeding rate of 3% of their body weight per day for 12 weeks. During the experiment fish blood parameters analysis, and liver histology tests were performed on 3 fish taken randomly from each tank at the beginning of the experiment and monthly. The results of blood chemistry analysis showed better results in the group fed with feed that contained fresh oil (A) compared to groups fed with feeds that contained oxidized oils (B and C), but no significant differences ( $P > 0.05$ ) between feed groups. Whereas the results of serum biochemical analysis showed significant differences ( $P > 0.05$ ) between feed groups during the experiment period, oxidized fish oil increased serum ALT, AST activity, and TCHO level ( $P < 0.05$ ), and decreased ALP activity. The liver histology test showed the best results in group A compared to oxidized oil groups (B, C), oxidized fish oil caused damage to the liver structure, and hepatocyte nuclear migration and lipid droplets were observed in liver samples from the oxidized oil groups. In conclusion, the present study demonstrates that oxidized fish oil may have a negative effect on the liver histology and blood parameters of Nile tilapia fingerlings.

**Keywords:** Oil Oxidation, Blood Parameters, Liver Histology, Nile Tilapia.

**Received:** 23 August 2022 \* **Accepted:** 23 September 2022 \* **DOI:** <https://doi.org/10.29329/ijjaar.2022.475.1>

\* **Corresponding author:**

Sana Yagoub Abdallah Tahir, Ege University, Graduate School of Natural and Applied Science, Department of Aquaculture Bornova, İzmir, Turkey.  
Email: [sana.agoub.at@gmail.com](mailto:sana.agoub.at@gmail.com)

## INTRODUCTION

The performance of aquaculture is affected by feed quality, seed quality, water quality, fish growth, feed conversion ratio, disease, etc (FAO, 2018). Vegetable oils (palm, soybean, sunflower, corn, and flaxseed oil) and fish oil are mainly used in aquaculture feeds (Turchini et al., 2009). Among oil sources, fish oils are best known and highly regarded for their high proportions of n-3 LC-PUFAs and fat-soluble vitamins A and D (Karrick, 1967).

Fishmeal and fish oil used in commercial aquaculture feeds contain high levels of polyunsaturated fatty acids n-3 (PUFAs). Therefore, are susceptible to oxidation (Trenzado et al., 2006; Laohabanjong et al., 2009). The oxidation products produced during the oxidation process are easily absorbed and transported to tissues (Gao et al., 2012).

In fish, symptoms related to the consumption of oxidized fish oil include reduced growth, poor survival, anemia, depletion of vitamins C and E, and liver degeneration (Gao et al., 2012; Wang et al., 2016; Yu et al 2020). Thus, this study aimed to investigate the effect of dietary oxidized anchovy oil on blood parameters and liver histology of (*Oreochromis niloticus*) and to provide data for better use of fish oils on aquafeeds.

## MATERIALS AND METHODS

### **Ethics statement**

The study was conducted according to the guidelines for fish studies provided by the Committee of Animal Ethics of Ege University, with the Protocol Number 2019 - 100.

### **Study location**

This experiment was carried out in Ege University, Experimental Animals Unit (Room No1) for three months between 10th March 2021 and 8th June 2021.

### **Oxidized fish oil preparation and peroxide analysis**

The oxidized fish oil was prepared by the following procedure (Chen et al., 2012): Fresh anchovy oil was oxidized by heating at 70°C with continuous air injection for 10 days. Peroxide value (POV) was monitored at 24 h intervals until the POV of 50 and 100 meq/kg<sup>-1</sup> was reached, according to the method of (AOAC, 2000, iodometric titration). Before preparing the diets, the oxidized fish oil and the fresh fish oil were both stored at -20°C to prevent further oxidation during storage.

### **Experimental diets**

Three diets were formulated to contain 35% crude protein and 8% fresh or oxidized fish oil. The experimental feeds were formulated from fish meal, soybean meal, wheat flour, vitamin and mineral premixes, and fresh anchovy oil. All solid ingredients were ground into powder and mixed thoroughly

with oil and water (60 °C) by hand, then pelleted to (3 mm in diameter) using a laboratory pellet machine (TY-432; Shanghai Taiyi Machinery). Then pellet feeds were dried at room temperature at 15 -20°C for 4 days and finally placed in plastic bags for fish feeding.

**Table 1.** Nutrient content (%) and peroxide level of the diets:

Content	Feed A	Feed B	Feed C
Dry matter	91.0	90.8	91.5
Crude protein	35.4	35.3	35.4
Crude fat	8.3	8.3	8.5
Crude ash	9.3	8.8	8.5
Peroxide level (meq/kg-1)	4.85	50.19	100.80

### Experimental procedures

The experiment was conducted in nine fiberglass tanks of 120 liter, in circulating system. A total of (450) Nile tilapia fingerlings with an average body weight of (15.07±0.58 g) were obtained from the Aquaculture Farm of the Ministry of Agriculture, Antalya, Turkey. The fishes were acclimated for two weeks in four tanks. After acclimation, the experimental fish were starved for 24 h, the initial weight and total length of each fish were taken, then stocked in three groups in triplicates at a density of 50 fish/tank. The experimental fish were fed with three test diets containing fresh and oxidized anchovy oil (POV= 4.9±0.42, 50.1±0.71, 100.80±1.69 meq/kg<sup>-1</sup>) twice a day at a rate of 3% of their body weight per day for 12 weeks. Each sampling (30 fish per tank) were randomly caught, their body weight and total body length were individually measured every 21 days. Clove oil was used as an anesthetic at a rate of 0.1 ml/L (Fernandes et al., 2017).

### Sample collection

During the experiment fish blood parameters analysis, and liver histology tests were performed on 3 fish taken randomly from each tank at the beginning of the experiment and monthly. Blood samples were collected from the caudal vein of the fish using a heparinized needle and syringes (3 ml) from 3 fish per tank and pooled into 1 tube as a blood sample, and transported to the laboratory for analysis.

### Sample analysis

Hematological analyses, including Red blood cell (RBC), white blood cell (WBC), Hemoglobin (HB), hematocrit (HCT), Mean Corpuscular Volume (MCV), mean corpuscular hemoglobin (MCH), mean corpuscular hemoglobin concentration (MCHC) were analyzed by Veterinary Blood Counting Device (HAVSET VH5R). And serum biochemical analyses such as Alanine transaminase (ALT), Aspartate transaminase (AST), Alkaline phosphatase (ALP), and Total-

cholesterol (TCHO) were analyzed using commercial kits on an automated biochemistry analyzer (FUJIFILM Dri-Chem NX 500V ic).

Morphological and histological analysis of liver samples was done using the method described by (Paul, 2017). The liver samples were fixed in 10% buffered formalin, dehydrated in graded ethanol series and embedded in paraffin. Sections were stained with haematoxylin and eosin (H&E). The sections were examined and photographed using a light microscope.

### Statistical analysis

One-way ANOVA (SPSS, 16.0) test was used to assess significant differences in growth rates and blood parameters between the experimental groups. Differences were considered significant at  $p < 0.05$ . The results were presented as Means $\pm$ SD (standard deviation).

## RESULTS

After 12 weeks of feeding trial in recirculating system (50 fish/tank, 120 liters) Nile tilapia fed with fresh oil showed better growth performance compared with the oxidized oil groups. And the hepatosomatic index (HSI) of oxidized oil groups was significantly higher ( $P < 0.05$ ) than the fresh oil group (Table. 2).

Blood parameters: oxidized fish oil did not affect significantly the amount of (WBC, RBC, HG, HCT, MCV, MCH, MCHC) of Tilapia fish. However, serum total cholesterol level and serum (ALT, AST) activity were significantly ( $P < 0.05$ ) increased in fish fed oxidized oil, and serum ALP activity was decreased (Figure. 1).

Liver histology: in the fresh oil group, there was no observed ballooning degeneration and hepatocytes nuclei were centrally located. However, liver ballooning degeneration, nuclear migration and hyperemia were observed in liver samples from the oxidized oil groups (Figure. 2).

**Table 2.** Growth performance of Nile tilapia fed diets containing different oxidized oil level.

Growth parameters	Group A (POV= 4.9 meq/kg <sup>-1</sup> )	Group B (POV= 50 meq/kg <sup>-1</sup> )	Group C (POV= 100 meq/kg <sup>-1</sup> )
Initial weight	15.32 $\pm$ 2.13 <sup>a</sup>	15.23 $\pm$ 0.90 <sup>a</sup>	15.36 $\pm$ 3.49 <sup>a</sup>
Final weight	68.24 $\pm$ 7.63 <sup>a</sup>	62.31 $\pm$ 9.80 <sup>a</sup>	64.49 $\pm$ 20.80 <sup>a</sup>
Feed Conversion Ratio (FCR)	1.32 $\pm$ 0.60 <sup>a</sup>	1.42 $\pm$ 0.59 <sup>a</sup>	1.43 $\pm$ 1.43 <sup>a</sup>
Survival rate (SR)	93.3 $\pm$ 5.03 <sup>a</sup>	92.0 $\pm$ 6.93 <sup>ab</sup>	88.0 $\pm$ 14.42 <sup>b</sup>
Hepatosomatic Index (HSI)	3.15 $\pm$ 0.40 <sup>a</sup>	3.47 $\pm$ 0.15 <sup>b</sup>	3.57 $\pm$ 0.13 <sup>c</sup>
Viscerosomatic index (VSI)	14.61 $\pm$ 1.10 <sup>a</sup>	15.41 $\pm$ 0.31 <sup>b</sup>	15.02 $\pm$ 0.03 <sup>c</sup>

Values represent means  $\pm$  SD, and values in the same row with different letters were significantly different ( $P < 0.05$ ). (A) Fresh fish oil diet group, (B) 50 meq/kg<sup>-1</sup> oxidized fish oil diet group, (C) 100 meq/kg<sup>-1</sup> oxidized fish oil diet group.

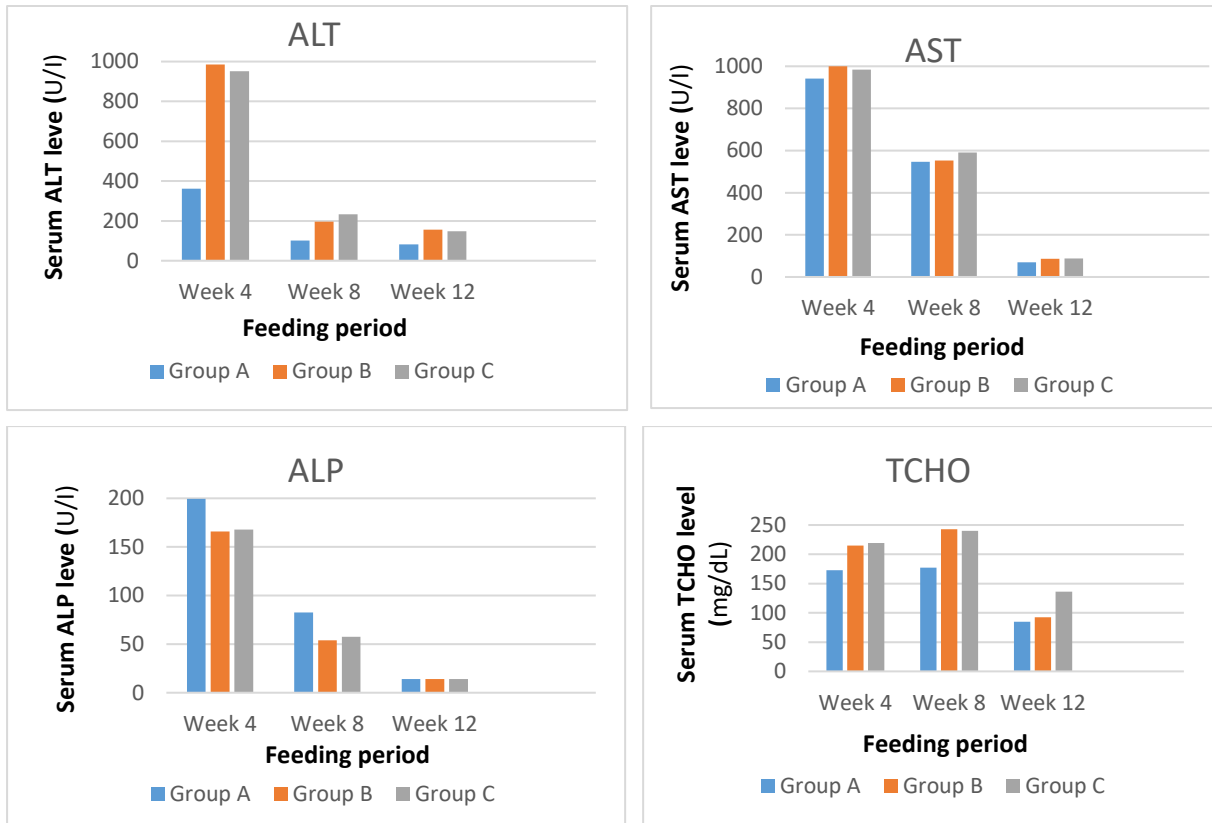


Figure 1. Serum biochemical parameters of fish groups during the experiment.




Figure 2. Liver histology of fish groups at the end of the experiment. (A) Fresh fish oil diet group, (B) 50 meq/kg<sup>-1</sup> oxidized fish oil diet group, (C) 100 meq/kg<sup>-1</sup> oxidized fish oil diet group. The white arrow represents ballooning degeneration, the red arrow represents hyperemia and the yellow arrow represents nuclear migration.

## DISCUSSION

Fish oil is an important source of lipid in fish diets. However, it is easily oxidized due to its high polyunsaturated fatty acid content. Oxidized fish oil produces harmful substances that negatively impact fish health (Long et al., 2022).

In the present study, oxidized anchovy oil with (50 and 100 meq/kg<sup>-1</sup>) peroxide level was used instead of fresh anchovy oil (4.85 meq/kg<sup>-1</sup>) in Nile tilapia feed. At the end of the experiment, the best growth performance showed in the fish group fed with feed containing fresh fish oil. It indicated that

oxidized fish oil had a negative effect on Nile tilapia growth performance during the experiment. Negative effects of oxidized fish oil on fish growth have been reported in GIFT Nile tilapia (Yu et al., 2020), *Pelteobagras fulvidraco* (Zhuo et al., 2017), Rainbow trout (Fontagné-Dicharry et al., 2018), Hybrid grouper (Long et al., 2022), *Siberian sturgeon* (Fontagné et al., 2006) when fed with feeds contained oxidized oils.

Serum AST and ALT activities have often been regarded as biomarkers for liver function, its activities may reflect the degree of liver injury. Dietary oxidized fish oil has also been confirmed to cause a significant increment in serum AST and ALT activities (Chen et al., 2019).

In the current study, the significantly increasing of serum (ALT, AST) activity on fish fed oxidized oils seems that oxidized fish oil caused liver tissue damage. Similar studies have been found in GIFT *Oreochromis niloticus* (Yu et al., 2020), *Ictalurus punctatus* (Liang et al., 2018), *Ictalurus punctatus* (Shi et al., 2021), when fed with oxidized oil. Whereas, our study result is not matched with the findings of Luo et al., (2021) in feeding (*Acipenser schrenckii*) with oxidized oil, which showed that oxidized oil did not affect on serum ALT, AST activity.

The liver, which acts as the center of metabolism and detoxification is sensitive to the toxicity of oxidized lipids (Peng et al., 2021). It was observed that feeding oxidized fish oil diets significantly increased the hepatosomatic index compared to fish fed fresh oil. It may due be to lipid deposition in the liver, thus the lipid content of the fish liver was significantly higher in fish groups fed with oxidized oil. The increased hepatosomatic index by oxidized oils was also observed in farmed GIFT (*Oreochromis niloticus*) when fed feed contained oxidized fish oil (Yu et al., 2020). The same result was reported in *Ictalurus punctatus* (Shi et al., 2021), *Litopenaeus vannamei* (Yang et al., 2015) *Acanthopagrus schlegeli* (Peng et al., 2009). However, our study result is not matched with the result reported by (Luo et al., 2021; Zhang et al., 2016) in rearing *Acipenser schrenckii* and *Lateo labrax*, which showed no significant differences in fish hepatosomatic index between fresh and oxidized oil groups.

Various changes in the liver histology of fish fed with feed contained oxidized oil indicated that the oil oxidation had a negative effect on the hepatic health of Nile tilapia fish. Negative effects of oxidized fish oil on fish liver histology have been reported previously in GIFT *Oreochromis niloticus* (Yu et al., 2020), *Litopenaeus vannamei* (Chen et al., 2019), hybrid grouper (Long et al., 2022), *Micropterus salmoide* (Chen et al., 2012) which showed hepatocyte damage, hepatocyte nucleus migration, and liver degeneration when fed with different levels of oxidized oils.

## CONCLUSIONS

The researching of feeding problems in fish production is not easy, and it may take months to see their negative effect.

In general the results of studies obtained in feeding fish with oxidized diets showed a negative effect on the fish body, whereas in some cases showed no effect. These differences may be depending on the species tolerance to oxidized oils and the experiment period.

In general, dietary oxidized fish oil used in the present study reduced the fish growth performance, caused damage in the liver structure, liver degeneration, and in addition increased serum (AST, ALT) activity.

In conclusion the present study indicated that oxidized-fish-oil has a negative effect on growth performance, liver structure, and liver function of cultured Nile tilapia. It is recommended to use fresh fish oils in fish diets.

### **Acknowledgments**

This research is a part of a Ph.D project, was supported by the fund of Ege University, Scientific Research Projects Coordination Unit (BAP), Project No. (FDK-2021-22458).

### **REFERENCES**

- AOAC (Association of Official Analytical Chemists, 2000. Official Methods of Analysis. 17th Edition, Gaithersburg, MD, USA, Method 965.33.
- Chen, S., Zhuang, Z., Yin, P., Chen, X., Zhang, Y., Tian, L., Niu, J. and Liu, Y., 2019. Changes in growth performance, haematological parameters, hepatopancreas histopathology and antioxidant status of pacific White shrimp (*Litopenaeus vannamei*) fed oxidized fish oil: Regulation by dietary myoinositol. *Journal of Fish and Shellfish Immunology*, 88: 53–64pp.
- Chen, Y.-J., Liu, Y.-J., Yang, H.-J., Yuan, Y., Liu, F.-J., Tian, L.-X., Liang, G.-Y. and Yuan, R.-M., 2012. Effect of Dietary Oxidized Fish Oil on Growth Performance, Body Composition, Antioxidant Defence Mechanism and Liver Histology of juvenile largemouth bass (*Micropterus salmoides*). *Aquaculture Nutrition*, 18: 321–331pp, doi: 10.1111/j.1365-2095.2011.00900.x.
- FAO (Food and Agriculture Organization of the United Nations), 2018. Improving the Performance of Tilapia Farming Under Climate Variation. FAO, Fisheries and Aquaculture Technical Paper, 608. Rome.
- Feng, Q-F., Wang, S-W., Huang, X-Z., Li, H., Liu, C-J., Lu, H., Chen, Y-J., Lin, S-M. And Luo, L., 2021. Effects of oxidized silkworm (*Bombyx mori L.*) pupae on growth performance, and intestine, liver and muscle histology and function of Gif Tilapia (*Oreochromis niloticus*). *Aquaculture Research*, 52:4127–4137, DOI: 10.1111/are.15251.
- Fernandes, I.M., Bastos, Y.F., Barreto, D.S., Lourenço, L.S. and Penha, J.M., 2017. The efficacy of clove oil as an anaesthetic and in euthanasia procedure for small-sized tropical fishes. *Braz. J. Biol*, 77(3): 444 – 450pp, <http://dx.doi.org/10.1590/1519-6984.15015>.
- Fontagné, S., Bazin, D., Brèque, J., Vachot, C., Bernarde, C., Thierry Rouault, T. and Bergot, P., 2006, Effects of dietary oxidized lipid and vitamin A on the early development and antioxidant status of Siberian sturgeon (*Acipenser baeri*) larvae, *Journal of Aquaculture*, 257: 400 – 411pp.

- Fontagné-Dicharry, S., Larroquet, L., Dias, K., Cluzeaud, M., Heraud, C. and Corlay, D., 2018. Effects of dietary oxidized fish oil supplementation on oxidative stress and antioxidant defense system in juvenile rainbow trout (*Oncorhynchus mykiss*). *Journal of Fish and Shellfish Immunology*, 74: 43–51pp.
- Gao, J., Koshio, S., Ishikawa, M., Yokoyama, S., Mamauag, R.E.P. ve Han, Y., 2012. Effects of dietary oxidized fish oil with vitamin E supplementation on growth performance and reduction of lipid peroxidation in tissues and blood of red sea bream (*Pagrus major*). *Aquaculture*, Volumes 356–357: 73–79pp.
- Karrick, N.L., 1967. Nutritional Value of Fish Oils as Animal Feeds. Chapter 24 reprinted from the book (Fish Oils), M. E. Stansby, editor, Avi Publishing Company, Westport, Connecticut, Circular 281, Washington, D.C.
- Laohabanjong, R., Tantikitti, C., Benjakul, S., Supamattaya, K. and Boonyaratpalin, M., 2009. Lipid oxidation in fish meal stored under different conditions on growth, feed efficiency and hepatopancreatic cells of black tiger shrimp (*Penaeus monodon*). *Aquaculture*, 286: 283–289pp, <http://dx.doi.org/10.1016/j.aquaculture.2008.09.038>.
- Liang, G., Li, X., Yang, H., Huan, D., Xu, Z., Leng, X., Gao, Q., 2018. Dietary oxidized oils decreased growth, antioxidative capacity, and negatively affected skin color of channel catfish (*Ictalurus punctatus*). *Journal of World Aquaculture Society*, 50: 692–706pp.
- Long, S., Dong, X., Yan, X., Liu, H., Tan, B., Zhang, S., Chi, S., Yang, Q., Liu, H., Yang, Y. and Zhang, H., 2022, The effect of oxidized fish oil on antioxidant ability, histology and transcriptome in intestine of the juvenile hybrid grouper (♀ *Epinephelus fuscoguttatus* × ♂ *Epinephelus lanceolatus*), *Aquaculture Reports*, 22:100921pp, <https://doi.org/10.1016/j.aqrep.2021.100921>.
- Luo, L., Yu, H., Ren, Y., Wei, H., Xing, W., Xu, G., Li, T. and Xue, M., 2021. Dietary oxidized fish oil negatively affected the feed utilization, health status and fillet quality of juvenile Amur sturgeon, *A. Schrenckii*. *Aquaculture*, 546 (2022): 737290 pp, <https://doi.org/10.1016/j.aquaculture.2021.737290>.
- Paul, M., 2017. Histological Slide Preparation of Fish Tissues (Paraffin Method). Muktic Chanda, Asutosh College, Kolkata, DOI: 10.13140/RG.2.2.15130.34243, 5p, [www.researchgate.net](http://www.researchgate.net).
- Peng, S., Chen, S., Qin, J.G., Hou, J., Yu, N., Long, Z., Li, E. and Ye, J., 2009. Effects of Dietary Vitamin E Supplementatin on Growth Performance, Lipid Peroxidation and Tissue Fatty Acid Composition ofn Black Sea Bream (*Acanthopagrus schlegeli*) Fed Oxidized Fish Oil. *Aquaculture Nutrition*, 15: 329–337, doi: 10.1111/j.1365-2095.2009.00657.x.
- Shi, Y., Hu, Y., Wang, Z., Zhou, J., Zhang, J., Zhong, H., Fu, G. and Zhong, L., 2021. The Protective Effect of Taurine on Oxidized Fish-Oil Induced Liver Oxidative Stress and Intestinal Barrier Function Impairment in Juvenile (*Ictalurus punctatus*). *Antioxidants*, 10: 1690pp, <https://doi.org/10.3390/antiox10111690>.
- Trenzado, C., Hidalgo, M.C., García-Gallego, M., Morales, A.E., Furné, M., Domezain, A., Domezain, J. and Sanz, A., 2006. Antioxidant enzymes and lipid peroxidation in sturgeon (*Acipenser naccarii*) and trout (*Oncorhynchus mykiss*), A comparative study. *Aquaculture*, 254: 758–767pp, <http://dx.doi.org/10.1016/j.aquaculture.2005.11.020>.
- Turchini, G.M., Torstensen, B.E. and Ng, W.-K., 2009. Fish oil replacement in finfish nutrition. *Reviews in Aquaculture*, 1: 10-57pp, <https://doi.org/10.1111/j.1753-5131.2008.01001.x>TÜİK, 2019. Su Ürünleri İstatistikleri, <http://www.tuik.gov.tr/>.



- Wang, J., Xu, H., Zuo, R., Mai, K., Xu, W. and Ai, Q., 2016. Effects of oxidised dietary fish oil and high-dose vitamin E supplementation on growth performance, feed utilisation and antioxidant defence enzyme activities of juvenile large yellow croaker (*Larimichthys crocea*). *British Journal of Nutrition*, 115: 1531–1538pp.
- Yang, S-P., Liu, H-L., Wang, C-G, Yang, P., Sun, C-B. and Chan, S-M., 2015. Effect of Oxidized Fish Oil on Growth Performance and Oxidative Stress of *Litopenaeus vannamei*. *Aquaculture Nutrition*, 21: 121-127.
- Yu, L., Wen, H., Jiang, M., Wu, F., Tian, J., Lu, X., Xiao, J. and Liu, W., 2020. Effects of ferulic acid on intestinal enzyme activities, morphology, microbiome composition of genetically improved farmed tilapia (*Oreochromis niloticus*) fed oxidized fish oil. *Aquaculture*, 528: 735543pp, doi.org/10.1016/j.aquaculture.2020.735543.
- Zhang, C.-X., Uang, F. H., Li, L., Wang, L., Song, K. and Mai, K.-S., 2016. Interactive Effects of Magnesium and Vitamin E on Growth Performance, Body Composition, Blood Parameters and Anti Oxidant Status in Japanese Seabass (*Lateolabrax japonicus*). *Journal of Aquaculture Nutrition*, 22: 708-722pp.
- Zhuo, L.X., Zhao, H.X., Huang, Y.H., Cao, J.M., Wang, G.X., Chen, B. and Sun, Y.P., 2017. Influences of oxidized fish oil on growth performance and antioxidant indexes of yellow catfish (*Pelteobagrus fulvidraco*) and the use of arginine as an intervention measure. *Chinese Journal of Animal Nutrition*, 29: 147-157pp.